



# Bio Vet Innovator Magazine

(Fueling The Future of Science...)

Volume 3 (Issue 5) MAY 2026



International Day for Biological Diversity - 22<sup>th</sup> May

Popular Article

## Photosensitization in Livestock

**Nirbhay Bhawsar<sup>1</sup> and Rudra Prayag chandel<sup>2</sup>**

1M.V.Sc. Scholar, Division of Extension Education,  
ICAR-Indian Veterinary Research Institute, Izatnagar,  
Bareilly, Uttar Pradesh -243122

2M.V.Sc. Scholar, Poultry Science,  
ICAR-Central Avian Research Institute, Izatnagar,  
Bareilly, Uttar Pradesh -243122

\*Corresponding Author: [drnirbhaybhawsar@gmail.com](mailto:drnirbhaybhawsar@gmail.com)

DOI: <https://doi.org/10.5281/zenodo.20300628>

Received: April 30, 2026

Published: May 09, 2026

© All rights are reserved by **Nirbhay Bhawsar**

### Abstract:

Photosensitivity is a condition in which animals become abnormally sensitive to sunlight, leading to significant health, production and reproduction losses and causing economic damage to farmers worldwide especially in countries like India and other South Asian regions near the equator. It mainly affects the skin, hair and eyes, with non-pigmented, young, sick or hairless animals being more susceptible compared to healthy, mature and pigmented ones. At the biological level, it occurs due to light-induced oxidative or chemical changes in the skin caused by endogenous or exogenous photosensitizing agents. This article summarizes the pathogenesis, diagnosis, treatment and preventive measures of photosensitization in animals.

**Keywords:** Photosensitization, Phototoxicity, Livestock, Skin Lesions, Sunlight Exposure.

### Introduction:

India possesses one of the largest livestock populations globally, as reported by BAHS (Basic Animal Husbandry Statistics), making effective animal health management highly important for livestock producers. Among various disorders, photosensitization is a common and economically significant condition in grazing animals, which develops when susceptible animals are exposed to sunlight (Clare, 1953). This condition occurs due to the activation of photodynamic substances by light in the range of 280–790 nm, causing increased sensitivity of non-pigmented or lightly pigmented skin to ultraviolet and visible radiation, ultimately resulting in inflammation and tissue damage (Sarigson *et al.*, 2012). Similar oxidative reactions are also observed in plants, where the formation of reactive oxygen species and free radicals may lead to cellular injury, and in animals, these photodynamic compounds accumulate in tissues and trigger skin lesions (Quinn *et al.*, 2014). Although it may resemble conditions such as sunburn, fungal dermatitis, and certain metabolic diseases, photosensitization differs in its mechanism because it is driven by light-reactive compounds, including plant-derived toxins such as *Lantana camara* (Smith *et al.*, 2012).

Citation: Nirbhay Bhawsar and Rudra Prayag chandel. (2026). Photosensitization in Livestock. In Bio Vet Innovator Magazine (Vol. 3, Issue 5, pp. 1–6) Bio Vet Innovator Magazine. <https://doi.org/10.5281/zenodo.20300628>

Therefore, in India's extensive livestock production system, early diagnosis along with preventive strategies such as controlling toxic plants, improving nutrition, and protecting animals from excessive sunlight is essential to minimize losses and ensure animal welfare.

### Causes of Photosensitization in Animals:

Photosensitization in animals is a toxicological condition that occurs when photodynamic substances accumulate in the body and react with ultraviolet (UV) radiation, leading to oxidative stress and cellular damage, mainly in non-pigmented skin (Radostits *et al.*, 2007). The condition is broadly classified into primary, secondary (hepatogenous), chemical/drug-induced and endogenous metabolic causes (Merck Veterinary Manual, 2023).

**1. Plant-Induced Causes (Primary Photosensitization):** Primary photosensitization occurs when animals ingest plants containing photodynamic compounds such as furocoumarins and related secondary metabolites, which circulate in the bloodstream and become activated under sunlight exposure (FAO, 2013). Common incriminated plants include *Lantana camara*, *Hypericum perforatum* and *Ammi majus*, which generate reactive oxygen species upon UV exposure, leading to skin cell damage (Merck Veterinary Manual, 2023). In this type liver function remains normal, so the damage is directly due to plant-derived photodynamic agents (Radostits *et al.*, 2007).



**Lantana Camara**

**2. Liver Dysfunction (Secondary or Hepatogenous Photosensitization):** Secondary photosensitization results from impaired hepatic function, which leads to the accumulation of phylloerythrin a chlorophyll breakdown product (Radostits *et al.*, 2007). Normally phylloerythrin is excreted through bile; however, liver damage caused by toxins, infectious diseases or hepatotoxic plants (e.g., pyrrolizidine alkaloid-containing species) results in its accumulation in blood (Merck Veterinary Manual, 2023). Upon sunlight exposure, this compound becomes photoactivated and causes severe dermatitis and tissue necrosis (FAO, 2013).

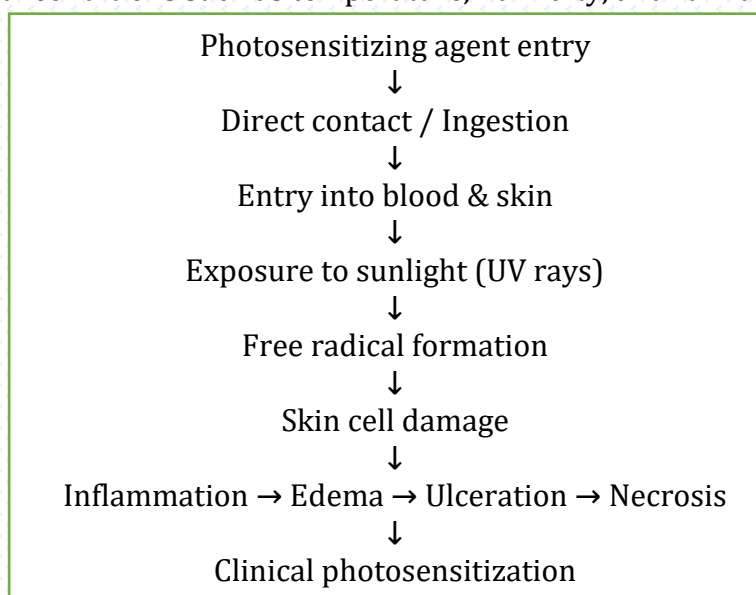
**3. Chemical and Drug-Induced Causes:** Certain chemicals and drugs can also induce photosensitization either directly or through liver metabolism disruption (Merck Veterinary Manual, 2023). Agents such as phenothiazines, chlorinated hydrocarbons and some antiparasitic drugs may increase skin sensitivity to UV radiation, especially under overdose or prolonged exposure conditions (Radostits *et al.*, 2007).

**4. Endogenous Metabolic Causes:** Photosensitization may also occur due to abnormal internal metabolic processes leading to accumulation of endogenous photoreactive compounds (FAO, 2013). Oxidative stress, impaired detoxification mechanisms and metabolic imbalance increase tissue

vulnerability to UV-induced damage, even without external toxic exposure (Merck Veterinary Manual, 2023).

### Pathogenesis:

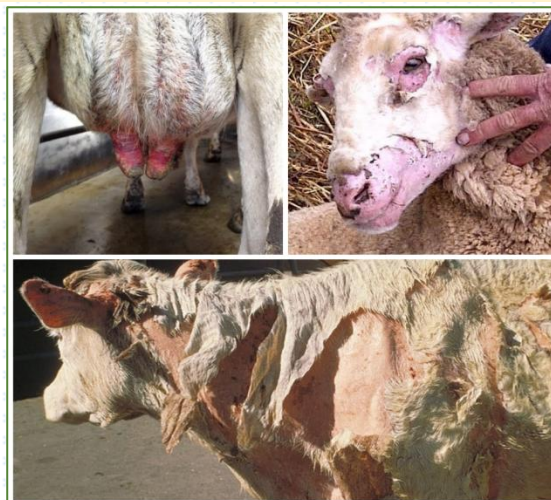Photosensitizing agents enter the animal body either through direct contact with the skin or via systemic absorption after ingestion and then get distributed to the skin where they may produce damage mainly through photocytotoxic reactions and less commonly, photoallergic reactions (Quinn *et al.*, 2014). In the photocytotoxic mechanism, these agents absorb ultraviolet (UV) light and form unstable, high-energy molecules that generate free radicals, leading to structural damage of cell membranes and lysosomal membranes. This results in increased membrane permeability, leakage of intracellular potassium and cytoplasmic contents and release of lysosomal enzymes, which ultimately causes inflammation, edema, ulceration and tissue necrosis in the affected skin areas (Barrington, 2017). The onset and severity of clinical signs depend on the nature and dose of the photosensitizing agent as well as the intensity and duration of sunlight exposure. In secondary photosensitization, liver dysfunction prevents normal excretion of chlorophyll metabolites, leading to accumulation of phytoporphyrin, which becomes photoactivated under sunlight and produces delayed but often more severe skin lesions (Quinn *et al.*, 2014). The susceptibility of animals to this condition is also influenced by several factors, including species and breed differences, degree of skin pigmentation, thickness of fur or hide, age, general health status and environmental conditions such as temperature, humidity, and rainfall (Gupta *et al.*, 2006).



### Clinical Signs of Photosensitization:

- **Early Signs:** In the initial stage of photosensitization, affected animals show behavioural and mild cutaneous changes soon after exposure to sunlight. They become restless and exhibit visible discomfort in sunlight, often trying to move into shade or avoid direct solar exposure a condition referred to as photophobia (Radostits *et al.*, 2007). Along with this mild erythema or redness of the skin appears in exposed and non-pigmented areas, indicating early inflammatory response. The skin also becomes

unusually sensitive to touch where even slight handling may cause irritation or pain due to early photodynamic damage (Merck Veterinary Manual, 2023).



- **Skin Lesions (Most Prominent Signs):** As the condition progresses, more severe skin lesions develop in sun-exposed regions such as the face, ears, muzzle and udder. There is marked swelling of the affected skin (edema) along with intense redness and inflammation, reflecting ongoing tissue injury (FAO, 2013). Animals often show intense itching (pruritus), leading to rubbing and scratching that further worsens the lesions. In some cases, vesicles or blisters may form, which later rupture and lead to crusting and scab formation. Serous fluid may ooze from damaged areas and in prolonged cases the skin becomes dry, thickened and less flexible. Severe photodynamic damage may eventually result in skin necrosis and ulceration (Radostits *et al.*, 2007).
- **Advanced or Severe Cases:** In advanced stages, the affected skin may begin to slough off due to extensive tissue death. Deep tissue involvement can occur, often complicated by secondary bacterial infections that further aggravate the condition (Merck Veterinary Manual, 2023). The necrotic tissue may produce a foul odour and healing, if it occurs, is often slow and may lead to permanent scarring or disfigurement of the affected areas.
- **Systemic Signs:** Along with skin lesions, systemic signs are also observed in severe cases. Animals show reduced feed intake (anorexia), depression and general weakness, indicating systemic stress. There is a noticeable loss of body condition over time, and in dairy animals, a decline in milk production is commonly recorded. In complicated or severe cases, mild to moderate fever may also be present due to secondary infection and inflammatory response (FAO, 2013).

### Treatment:

At present there is no specific antidote available for photosensitizing toxins therefore, treatment is mainly supportive and aimed at eliminating the causative agent and reducing clinical signs. Affected animals should be immediately removed from sunlight and kept in dark or well-shaded areas for about 5-7 days to prevent further activation of photodynamic compounds and worsening of skin lesions (Robson, 2007). Symptomatic therapy includes the use of soothing topical preparations such as demulcents along with antibiotic and corticosteroid ointments to control inflammation and prevent secondary infections (Merck Veterinary Manual, 2023). In more severe cases, systemic antihistamines and antibiotics may be administered to manage allergic reactions and bacterial complications. The use of laxatives or saline purgatives helps in faster removal of toxic plant material from the gastrointestinal tract in cases of plant-

induced photosensitization. Liver-supporting drugs and hepatoprotective tonics are also recommended to maintain hepatic function and reduce further damage in secondary cases (Robson, 2007).

### Prevention:

Prevention of photosensitization mainly depends on proper animal management and reducing exposure to both sunlight and toxic plants. Animals should be provided with adequate housing facilities such as sheds or shelters to minimize direct exposure to intense sunlight, particularly in high-risk regions (FAO, 2013). Prompt veterinary intervention is important as early treatment reduces severity and complications. Proper grazing and feeding management should be followed to prevent ingestion of photosensitizing or toxic plants, especially in natural pasture systems. Stall-feeding is preferred during high-risk periods. Animals suspected of genetic susceptibility should not be used for breeding purposes. During drought conditions, when animals are more likely to consume harmful plants due to feed scarcity, sufficient supply of safe and balanced fodder should be ensured to avoid plant-related photosensitization (Radostits *et al.*, 2007).

### Conclusion:

Photosensitization is an important toxicological and management-related disorder in livestock that can cause serious skin lesions, pain, reduced productivity and economic losses to farmers. The condition develops when photodynamic compounds present in plants, chemicals or metabolic by-products become activated by sunlight and damage exposed tissues, particularly in non-pigmented skin. Because India has a large livestock population and many animals depend on open grazing systems, the risk of exposure to toxic plants and intense sunlight is considerable. Effective control of this condition depends on early recognition of clinical signs, prompt supportive treatment, removal of the causative source and protection of animals from sunlight. Long-term prevention requires proper pasture management, balanced nutrition, safe housing and farmer awareness regarding toxic plants and risk factors. Therefore, timely veterinary care and improved management practices are essential to reduce the incidence of photosensitization and to safeguard animal health, welfare and farm productivity.

### References:

- Barrington, R. (2017). *Photosensitization and phototoxic skin disorders in domestic animals*. Journal of Veterinary Dermatology, 28(3), 145–152.
- Basic Animal Husbandry Statistics. (2024). *Basic animal husbandry statistics 2024*. Department of Animal Husbandry and Dairying, Government of India.
- Blood, D. C., Radostits, O. M., & Henderson, J. A. (1989). *Veterinary medicine* (7th ed.). Baillière Tindall.
- Clare, N. T. (1953). Photosensitization in grazing animals. *New Zealand Veterinary Journal*, 1(1), 6–14.

- Constable, P. D., Hinchcliff, K. W., Done, S. H., & Grünberg, W. (2017). *Veterinary medicine: A textbook of the diseases of cattle, horses, sheep, pigs and goats* (11th ed.). Elsevier.
- Food and Agriculture Organization. (2013). *Dairy production and products: Housing and management*. FAO.
- Gupta, R. C., Kadel, W. L., & Dudley, M. (2006). Environmental and species factors influencing photosensitization in livestock. *Veterinary Toxicology Review*, 12(2), 89–97.
- Merck Veterinary Manual. (2023). *Photosensitization in animals*. Merck & Co., Inc. Retrieved from <https://www.merckvetmanual.com>
- Munday, J. S. (2011). Photosensitization in grazing herbivores: A review. *Veterinary Journal*, 189(2), 123–129.
- NRC. (2001). *Nutrient requirements of dairy cattle* (7th rev. ed.). National Academies Press.
- Osweiler, G. D. (1996). *Toxicology*. Williams & Wilkins.
- Quinn, J. C., Munday, J. S., & Worth, A. J. (2014). Photosensitization in cattle, sheep and horses: Pathogenesis and clinical presentation. *New Zealand Veterinary Journal*, 62(4), 189–198.
- Radostits, O. M., Gay, C. C., Hinchcliff, K. W., & Constable, P. D. (2007). *Veterinary medicine: A textbook of the diseases of cattle, horses, sheep, pigs, and goats* (10th ed.). Saunders Elsevier.
- Riet-Correa, F., Medeiros, R. M. T., & Schild, A. L. (2009). Plant poisonings causing photosensitization in ruminants. *Toxicon*, 54(7), 1054–1062.
- Robson, S. (2007). Management and treatment of photosensitization in farm animals. *Australian Veterinary Practitioner*, 37(2), 74–79.
- Sarigson, R., McKenzie, R., & Peterson, G. (2012). Mechanisms of photodynamic skin injury in domestic animals. *Veterinary Pathophysiology Journal*, 18(1), 22–30.
- Smith, B. P., George, L. W., & House, J. K. (2012). *Large animal internal medicine* (5th ed.). Mosby Elsevier.
- Stöber, M. (2005). Skin diseases associated with photosensitivity in cattle. *Bovine Practice*, 39(1), 33–40.
- Taylor, S. M. (2015). *Large animal dermatology*. Wiley-Blackwell.
- Tokarnia, C. H., Döbereiner, J., & Peixoto, P. V. (2012). *Poisonous plants affecting livestock in tropical countries*. CAB International.